Morphea and Lichen Sclerosus 44

Martin Röcken and Kamran Ghoreschi

Morphea and lichen sclerosus (LS) are inflammatory skin diseases that ultimately evolve into two distinct modes of cutaneous sclerosis. In morphea, there is inflammation of the dermis that may extend into subcutaneous structures. Lichen sclerosus is primarily a disease of the genital mucosa (and less often extragenital sites) that affects the epidermis and the dermis. Morphea may lead to joint contractures and atrophy of underlying muscle, but there is no involvement of internal organs. The exceptions are the ocular and neurologic symptoms seen in a small minority of patients with linear morphea of the head or Parry–Romberg syndrome, in which there is extension into underlying muscles, bones, and occasionally deeper structures. While some patients may develop both disorders simultaneously, they are addressed separately because of their distinct features and different but overlapping therapeutic approaches.

MORPHEA

Synonyms/subtypes: ▪ Localized scleroderma ▪ Circumscribed scleroderma ▪ Plaque-type morphea ▪ Linear morphea – linear scleroderma ▪ Morphea *en coup de sabre* – scleroderma *en coup de sabre* ▪ Deep morphea – morphea profunda

Key features

- Asymmetric sclerotic plaques, usually 2–15 cm in diameter
- Active lesions can have a lilac border with central hypo- or dyspigmentation, while inactive lesions often become hyperpigmented
- The sclerosis may extend deeply into the fat or underlying structures (e.g. fascia, muscle, bone), causing disability
- With the exception of ocular or neurologic symptoms in patients with linear morphea of the head, associated systemic disease is not observed
- Often progresses for several years, then regresses; the linear subtype is usually persistent

INTRODUCTION

Morphea is a clinically distinct inflammatory disease, primarily of the dermis and subcutaneous fat, which ultimately leads to a scar-like sclerosis. The small vessel changes, inflammatory infiltrate, and ultimate structural modifications are identical in morphea and systemic sclerosis (SSc), but the two diseases are distinct entities that can be distinguished clinically. In addition, their triggers presumably differ and coexistence of morphea and SSc is rare[1]. Morphea has an asymmetric patchy or linear distribution. In contrast, SSc begins either as symmetric tightening of the fingers and hands that extends progressively toward the forearms (*limited cutaneous* SSc [lcSSc]) or as symmetrically extending sclerosis of the trunk and proximal upper extremities (*diffuse cutaneous* SSc [dcSSc]). Rarely, generalized morphea may resemble early dcSSc. The presence of Raynaud phenomenon, digital sclerosis, and involvement of the gastrointestinal tract and the lung also allows differentiation of SSc from morphea. Distinguishing between deep morphea and eosinophilic fasciitis can prove more difficult – whether these two disorders represent distinct entities or simply the ends of a broad clinical spectrum remains debatable, e.g. eosinophils may be present at the inflammatory border of morphea[2].

Morphea can cause significant morbidity as a result of pain, skin tightness, and impaired joint mobility. In ~10% of patients with morphea, sclerosis leads to significant contractures, growth retardation, and even micromelia, resulting in long-term functional disability[3]. Disease activity correlates with reduced quality of life[4].

HISTORY

A disease with thickened skin was first mentioned by Hippocrates (400 BCE). The term "scleroderma" is derived from the Greek words *skleros* (hard or indurated) and *derma* (skin). The first description of a generalized "hardness" of the skin in a young woman was by an Italian physician, Carlo Curzio, in 1753; the French physician Gintrac coined the term "sclérodermie" in 1847. Thomas Addison has been credited with the first detailed description of morphea in 1854, which he referred to as Alibert's keloid syndrome. In 1924, Matsui described the typical histopathologic changes of scleroderma and in 1930 O'Leary and Nomland elaborated on the distinctive features of SSc versus morphea.

EPIDEMIOLOGY

Even though morphea has been long recognized as a well-defined entity, few population-based studies exist. A survey from Olmsted County, Minnesota attempted to register all patients with the disorder from 1960 to 1993[5]. During this period, the annual incidence rate was 27 per million. According to this study, 56% of patients had plaque-type, 20% linear, 13% generalized, and 11% deep morphea[5].

The prevalence of morphea increases with age, occurring in ~500 and 2200 per million at ages 18 and 80 years, respectively[3]. The disease is more prevalent in women than in men (2.6 : 1), with the exception of linear morphea, which has no sex preference. Data published on the incidence and prevalence of morphea probably reflect an underestimation, as they critically depend on clinical recognition and diagnosis.

Morphea is rarely life-threatening. In the Olmsted County study, the survival rate of patients with morphea was not significantly different from that of the general population[5]. However, in 11% of the patients, substantial disability occurred. This is of particular concern since disability occurs primarily with linear morphea, which has its onset before age 18 years in two-thirds of patients[3,4].

PATHOGENESIS

Autoantibodies are usually as prevalent in morphea as in the general population, with two exceptions: (1) an increased prevalence of anti-single strand DNA (ssDNA), -topoisomerase IIα, -phospholipid, -fibrillin-1, and -histone antibodies (AHA) in patients with morphea; and (2) high titers of anti-nuclear antibodies (ANA) in juvenile patients with linear morphea and individuals with generalized morphea. In patients with linear morphea, the presence of ssDNA antibodies or AHA seems to be associated with increased risk of functional impairment[6].

Neither histology nor immunohistology of a single lesion will distinguish between morphea and SSc. In most clinicopathologic reviews, it is assumed that the two diseases are triggered by distinct events. However, the development of sclerosis following the initiating event seems to follow a common pathway. It is therefore assumed that pathogenic steps leading to SSc also contribute to the development of morphea, so they will be included in this discussion.

Currently, sclerosis of the skin is thought to involve three major, closely connected components: vascular damage, activated T cells, and altered connective tissue production by fibroblasts (Fig. 44.1)[7].

Downloaded for Anonymous User (n/a) at Egyptian Knowledge Bank from ClinicalKey.com by Elsevier on March 10, 2024. For personal use only. No other uses without permission. Copyright ©2024. Elsevier Inc. All rights reserved.

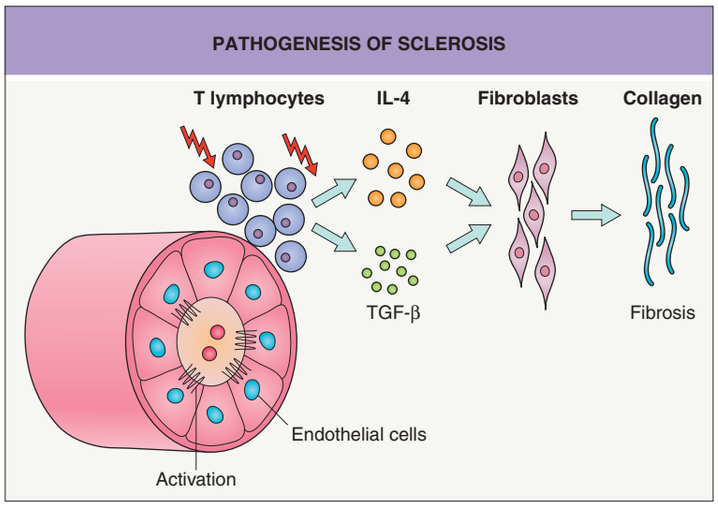

Fig. 44.1 Pathogenesis of sclerosis. Three components are involved during the formation of sclerosis: vascular damage, lymphocyte activation, and altered connective tissue production. IL, interleukin; TGF, transforming growth factor.

Vascular Changes

A prominent feature of advanced sclerosis is a reduction in the number of capillaries. Studies performed in SSc suggest that hypoxia resulting from microvascular injury is a very early, or even the primary, event. Endothelial cells respond to various stimuli, including vascular endothelial growth factor (VEGF), platelet-derived growth factor (PDGF), and transforming growth factor-β (TGF-β) (see Ch. 102). In the sera of patients with SSc, markers indicative of endothelial cell activation (e.g. soluble adhesion molecules, VEGF) are elevated. Morphologic changes principally affect capillaries and small arterioles, and the initial changes in SSc include expression of adhesion molecules and endothelial swelling, followed by thickening of the basement membrane and intimal hyperplasia. An extrapolation is that similar changes may occur early on in morphea.

Control of Fibroblast Function by T Cell-Derived Cytokines

Pioneering work by E. Carwile Leroy showed that *in vitro* cultured fibroblasts isolated from sclerotic tissue produce increased amounts of collagen (types I, II, and III) and other extracellular matrix proteins. These fibroblasts can maintain this phenotype for weeks over several passages. This raised the question as to whether SSc results from an inborn or acquired error in collagen metabolism within fibroblasts. Today, most data favor the concept that abnormal collagen production is directed by surrounding cells. T cells in particular have the capacity to modify collagen synthesis by fibroblasts, and T cells are regularly present, at least early on, in a perivascular location and especially at the leading edge of developing sclerosis (see Fig. 44.1).

Enhanced production of collagen and other extracellular matrix proteins is induced by T cell-derived cytokines, especially interleukin (IL)-4, IL-13, IL-17A, and TGF-β[8]. IL-4 is produced by $CD4^+$ T helper type 2 (Th2) lymphocytes (see Ch. 4) and can directly enhance TGF-β production[9]. Macrophages activated via the IL-4 receptor α (IL-4Rα) have been shown to influence collagen fibril assembly and promote fibrosis[10]. In contrast, production of collagen and other extracellular matrix proteins can be significantly suppressed by interferons that are associated with Th1 lymphocytes[9,10]. Th1 differentiation also implicates IL-12 signaling via the transcription factor STAT4. Of note, an association between *STAT4* polymorphisms (e.g. rs7574865) and susceptibility to SSc, especially the limited subtype, has been reported[11]. In a rare form of dominantly inherited pansclerotic morphea, gain-of-function variants in *STAT4* were detected, with JAK inhibition leading to reduction of the hyperinflammatory fibroblast phenotype *in vitro* and clinical improvement[11a]. Additional susceptibility loci associated with SSc include immune-related genes (e.g. *CD247*, *IRF5*, *HLA* region)[12] and the promoter region of the gene that encodes connective-tissue growth factor (CTGF)[13].

Circulating levels of the chemokine ligand CXCL4 (secreted by plasmacytoid dendritic cells) have been found to be significantly elevated in SSc[14]. Increased CXCL4 levels correlated with a higher prevalence of lung fibrosis and faster progression of skin fibrosis[14]. Interestingly, CXCL4 promotes the Th2 cytokines IL-4 and IL-13 and has anti-angiogenic properties.

IL-4 is the most potent force in driving differentiation of Th2 lymphocytes (see Fig. 4.9)[15]. Because IL-4 enhances pathologic collagen production by fibroblasts and induces recruitment of eosinophils, it is believed that immune responses dominated by IL-4- as well as IL-13- and TGF-β-producing cells are critical in the initiation of skin sclerosis[8,10]. This concept is supported by clinical and experimental data:

- *In situ* analysis of the advancing inflammatory margins of skin sclerosis revealed predominantly IL-4 expression.
- Th2-associated IL-13 and IL-33 have been shown to promote skin fibrosis in mice, and early treatment of scleroderma-developing mice with anti-IL-4 antibodies prevented scleroderma.
- Th2-like regulatory T (Treg) cells present in the skin of patients with SSc produce IL-4 and IL-13 and are responsive to IL-33[16].
- Systemic retinoids (which interact with TGF-β signaling) appear to reduce pathologic collagen synthesis by fibroblasts and may improve skin sclerosis in patients with chronic GVHD[17,18].
- Th2-promoting CXCL4 is so closely associated with SSc that it has been suggested as a biomarker for SSc[14].

One theoretical therapeutic approach for morphea would be to redirect Th2 responses into Th1 responses. Unfortunately, placebo-controlled clinical trials of the Th1-inducing cytokines IFN-γ or IFN-α in patients with morphea produced negative results[19]. The finding of elevated expression of IFN-related factors (e.g. CXCL9, CXCL10) in the skin and serum of cohorts with active morphea might provide an explanation[20], as it suggests that Th2 and Th1 cells may be activated simultaneously. Reports of the development of morphea and SSc during treatment with anti-PD-1 antibodies[21] also point to the importance of activated T cells in their pathogenesis. It remains to be determined whether highly effective, broader inhibitors of the Th2 cytokines IL-4 and IL-13 or other morphea-associated T cell responses could help prevent the inflammatory phase of morphea and attendant skin sclerosis. More recently, antibodies directed against type 1 IFN-triggered dendritic cell-derived epiregulin, which blocked activation of EGFR on fibroblasts and subsequent paracrine NOTCH activation, were shown to reverse fibrosis in skin explants[21a].

Lastly, when SSc fibroblasts are compared to control fibroblasts, there are differences in intracellular signaling proteins. Examples include activation of p38 mitogen-activated protein kinase and higher levels of Ha-Ras protein and reactive oxygen species. These findings plus data from animal studies demonstrating a link between skin fibrosis and pro-oxidative agents support hypoxia and oxidative stress as key factors in the pathogenesis of skin sclerosis.

Animal Model and Genetics

Currently, the best animal model for studying pathogenic events in SSc is the tight skin (TSK) mouse (Fig. 44.2). A partial duplication of the fibrillin-1 gene is thought to be responsible for the increased synthesis and accumulation of collagen in the skin and internal organs of TSK mice. TSK mice not only have increased collagen deposits, but also the collagen fibers are reduced in length and the quantity of hydroxyproline is increased in the dermis. Moreover, the mice have high antibody titers against topoisomerase I and fibrillin-1, similar to patients with SSc and morphea, respectively. One major difference is that blood vessels remain uninvolved in TSK mice, demonstrating that sclerosis of the skin can develop in the presence of apparently normal vessels[22]. The phenotype can be transferred from diseased animals to healthy syngeneic mice via bone marrow cells (see Fig. 44.2).

Fibroblasts from TSK mice have elevated IL-4Rα expression and back-crossing the TSK mice onto a genetic background that either cannot respond to IL-4 or is deficient in producing TGF-β prevents skin sclerosis. Moreover, this back-cross normalizes collagen length, skin thickness, and hydroxyproline content and prevents antibody formation to topoisomerase I (see Fig. 44.2)[22]. In this murine model of SSc, interventions that promoted Th1 responses or targeted PDGF receptor activity (e.g. imatinib) reduced dermal thickening and fibrosis[23]. More recent strategies for improving experimental skin fibrosis have focused on the role of platelet-derived serotonin[24], β-integrins, TGF-β[25], and

Downloaded for Anonymous User (n/a) at Egyptian Knowledge Bank from ClinicalKey.com by Elsevier on March 10, 2024. For personal use only. No other uses without permission. Copyright ©2024. Elsevier Inc. All rights reserved.

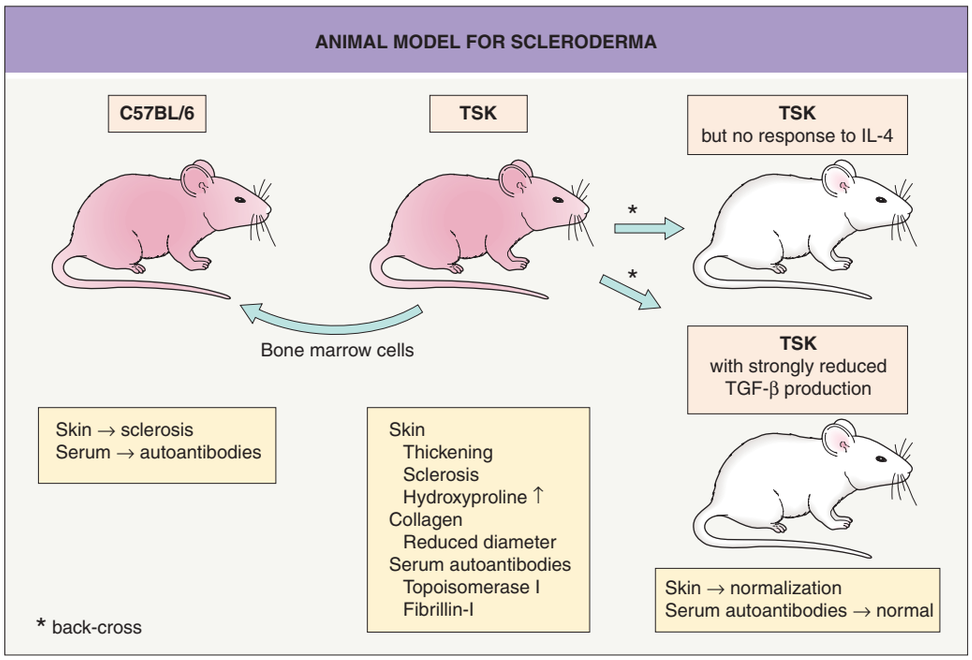

Fig. 44.2 Animal model for scleroderma. Transfer of scleroderma phenotype from diseased animals (TSK mice) to healthy syngeneic mice (C57BL/6) by bone marrow cells. Lack of tight skin and autoantibody production by back-crossing TSK mice with mice that cannot respond to IL-4 or mice that produce minimal amounts of TGF-β. IL, interleukin; TGF, transforming growth factor; TSK, tight skin strain of mice.

Janus kinases[26]. Of note, estrogen inhibition can exacerbate experimental dermal fibrosis driven by TGF-β[27].

In addition to the phenotypic similarities, the genetic locus associated with the TSK phenotype appears to be related to the risk of developing SSc. In humans, this susceptibility locus is on chromosome 15q in a region that contains the fibrillin-1 gene (*FBN1*); mutations in *FBN1* have been detected in patients with stiff skin syndrome (see Ch. 43)[28].

Triggering Events

Most immunologic and metabolic studies have been directed toward understanding SSc, and the question remains as to whether they can also explain focal, asymmetric inflammation and sclerosis of the skin. The major discriminating factor between morphea and SSc might be the triggering event, with morphea being caused by a local trigger within the skin and SSc initiated by a systemic insult. The putative local triggering events for morphea include mechanical trauma, injections, vaccinations[29], and X-irradiation.

These questions initiated the search for potential triggers and studies of diseases that share clinical features with morphea and SSc. One intensively investigated area was the potential role of infection with *Borrelia burgdorferi*. The isolation of *B. burgdorferi* from the skin of some selected patients with morphea originally supported this speculation. However, larger studies failed to confirm this initial observation[30]. Thus, this theory has been abandoned.

CLINICAL FEATURES

As outlined in Table 44.1, there are several classification schemes for morphea[31–34]. Major forms include plaque-type (circumscribed), linear, generalized, and other less common variants (e.g. nodular or keloidal). There are also inflammatory syndromes leading to superficial or deep sclerosis of the skin that resemble morphea (i.e. morpheaform; see below). Patients with morphea do not have Raynaud phenomenon or involvement of internal organs, except for underlying fascia, muscle, and bone in some patients with linear morphea and the occasional patient with linear morphea of the head who has ocular or neurologic symptoms. In rare patients with presumptive morphea, clinically insignificant fibrosis of the lung or slightly reduced esophageal motility has been detected radiographically or by scintigraphy. Clinically relevant involvement of internal organs is observed in certain types of pseudoscleroderma (see Ch. 43).

FOUR MORPHEA CLASSIFICATION SCHEMES			
Peterson (1995)[31]	**Padua (2006)[32]**	**European Dermatology Forum (2017)[33]**	**Dallas–Pittsburgh (proposed 2021)[34]**

Subtypes
• Plaque
  • Plaque
  • Guttate
  • Superficial
  • Lichen sclerosus
• Generalized
• Bullous
• Linear
  • Extremities
  • *"En coup de sabre"*
  • Parry–Romberg
• Deep
  • Morphea profunda
  • Subcutaneous
  • Eosinophilic fasciitis
  • Pansclerotic
	Subtypes
	• Circumscribed
	  • Superficial
	  • Deep
	• Linear
	  • Trunk or limbs
	  • Head
	• Generalized
	• Pansclerotic
	• Mixed
		Subtypes
		• Limited
		  • Plaque
		  • Guttate
		  • Superficial
		• Generalized
		  • Generalized
		  • Pansclerotic
		• Linear
		  • Extremities
		  • *"En coup de sabre"*
		  • Parry–Romberg
		• Deep
		• Mixed
		• Eosinophilic fasciitis
			Subtypes
			• Circumscribed
			• Linear
			• Generalized
			  • Generalized
			  • Pansclerotic
			• Mixed
			Modifiers
			• Superficial
			• Deep
			• Keloidal
			• Bullous

Table 44.1 Four morphea classification schemes. A recent cross-sectional study that included 944 adult and pediatric patients with morphea from two prospective cohorts compared three previously published morphea classification schemes. The Padua criteria performed best (95%) in classifying patients into groups with cohesive demographic and clinical features, compared with the Peterson (56%) and European Dermatology Forum (52%) criteria. Based on their findings, a modified morphea classification scheme was formulated[34].

Plaque-Type (Circumscribed) Morphea

Plaque-type (circumscribed) morphea, the most frequent variant, is characterized by the insidious onset of a slightly elevated, erythematous or violaceous, slightly edematous plaque that undergoes centrifugal expansion (Fig. 44.3). It is generally asymptomatic and therefore frequently goes unnoticed by the patient. The central portion of the progressing lesion starts to transform into sclerotic, scar-like tissue. Depending on the depth of the sclerosis, the skin becomes progressively indurated. Centrally, it can acquire a shiny white color and peripherally, a violaceous or "lilac" ring (Fig. 44.4A). Postinflammatory hyperpigmentation often dominates over the white sclerosis as the lesions mature (Fig. 44.4B).

Downloaded for Anonymous User (n/a) at Egyptian Knowledge Bank from ClinicalKey.com by Elsevier on March 10, 2024. For personal use only. No other uses without permission. Copyright ©2024. Elsevier Inc. All rights reserved.

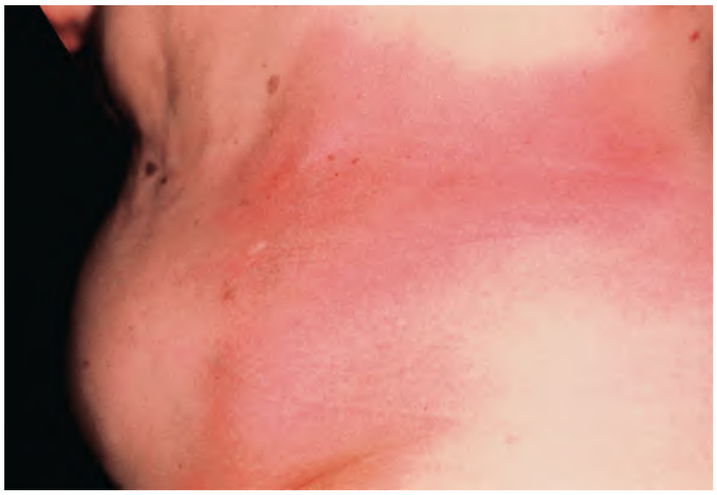

Fig. 44.3 Early inflammatory plaque-type (circumscribed) morphea of the trunk. Early-stage lesion presenting as an erythematous edematous plaque.

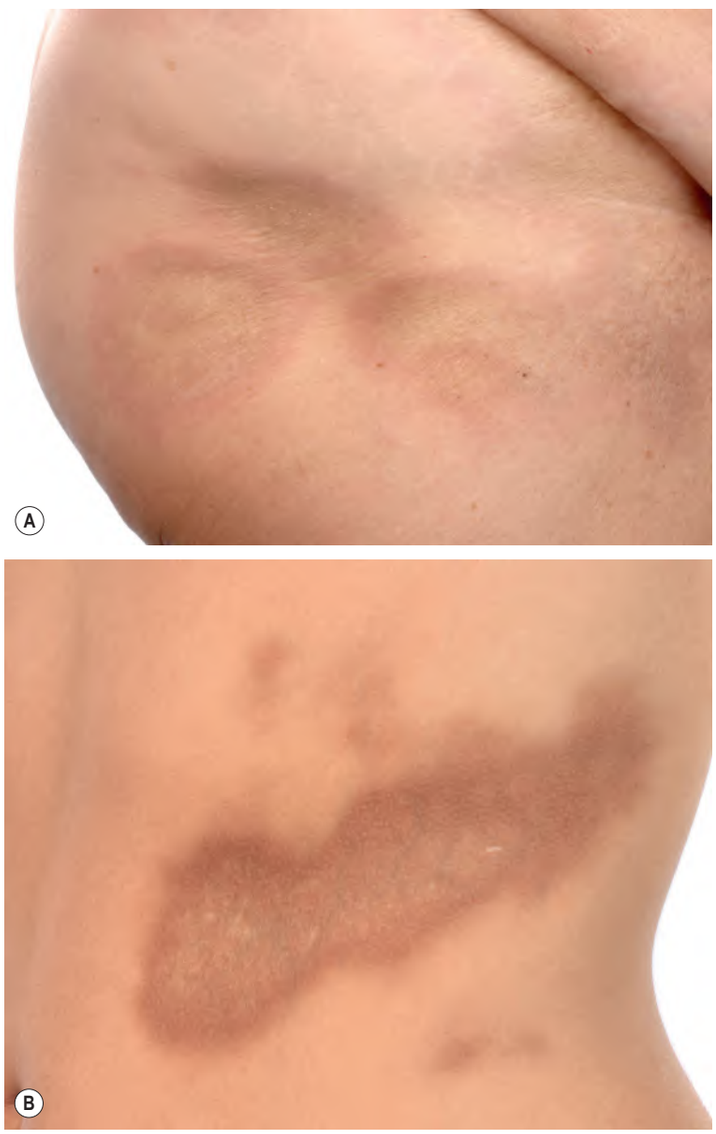

Fig. 44.4 Plaque-type (circumscribed) morphea. A Sclerotic plaques with the characteristic lilac-colored rim. Histologic findings will differ depending upon whether the biopsy specimen is obtained from the inflammatory edge or the central area of sclerosis (see Fig. 44.12). **B** The predominant lesion is a large, well-demarcated, hyperpigmented plaque that is depressed centrally; the trunk is a common location for plaque-type morphea.

Skin structures such as hairs and sweat glands are frequently lost. Some patients complain of itch, perhaps due to associated xerosis. Once the "lilac" ring vanishes, the lesion's progression also halts. Although this inflammatory margin may be difficult to appreciate, especially in linear sclerosis, it is an important indicator of clinical activity.

The plaques of morphea most commonly develop on the trunk and in general are between 2 and 15 cm in diameter. They are usually multiple and asymmetric, but marked variation exists. Individual lesions may enlarge significantly or remain stable in size.

The course of morphea is also variable. In most patients, morphea progresses over 3–5 years, then arrests and eventually resolves spontaneously. However, residual atrophy and dyspigmentation are commonly observed. Patients rarely have relapsing disease for more than 5 years, but may have sequelae such as calcinosis cutis (see Fig. 50.2)[35].

Variants

Various manifestations of morphea have become associated with specific names. They do not really reflect unique entities, but rather different morphologic features, distribution patterns, or depth of involvement. In most patients, morphea seems to be randomly distributed. However, in some patients, the lesions are unilateral, and they may follow dermatomes or the lines of Blaschko.

- **Guttate morphea** presents primarily as multiple, rather superficial, nummular plaques. Even though relatively small, they may become deeply indurated.
- **Atrophoderma of Pasini and Pierini** is considered by some to be a very superficial variant of plaque-type morphea, while others consider it to be a separate entity in the differential diagnosis of "burnt-out" morphea (see Ch. 99). Hyperpigmented patches are seen most commonly on the posterior trunk; occasionally, lesions follow the lines of Blaschko (linear atrophoderma of Moulin).
- **Deep morphea** denotes inflammation and sclerosis that affects primarily the deep dermis and subcutaneous fat and may even involve underlying structures (e.g. the fascia) (Fig. 44.5A). Patients normally develop a small number of hard deep plaques that may impair motility of the skin; ultimately, lesions may calcify, leading to dystrophic calcinosis cutis. Because of the location of the sclerosis, individual lesions may resemble eosinophilic fasciitis (Fig. 44.5B and see Ch. 43).

Fig. 44.5 Comparison of deep morphea and eosinophilic fasciitis. A Note the "pseudo-cellulite" appearance of the involved skin of the thigh in deep morphea. **B** In eosinophilic fasciitis, the level of fibrosis is also deep, resulting in a similar rippled appearance. This patient had the eosinophilic fasciitis-like form of chronic GVHD, also referred to as chronic GVHD-related fasciitis. *B, Courtesy Edward Cowen, MD.*

Downloaded for Anonymous User (n/a) at Egyptian Knowledge Bank from ClinicalKey.com by Elsevier on March 10, 2024. For personal use only. No other uses without permission. Copyright ©2024. Elsevier Inc. All rights reserved.

Fig. 44.6 Nodular or keloidal morphea. Multiple firm, hyperpigmented nodules mimicking keloids in a 10-year-old girl. *Courtesy Julie V. Schaffer, MD.*

Fig. 44.7 Parry–Romberg syndrome. Unilateral sclerosis and loss of subcutaneous fat, leading to facial asymmetry. *Courtesy Lorenzo Cerroni, MD.*

- In **nodular or keloidal morphea**, inflammation within the dermis leads to thick, keloid-like nodules (Fig. 44.6) or bands. It can be clinically indistinguishable from indurated keloids.
- In rare patients, especially those where sclerosis of the skin is associated with diffuse, rapidly progressive edema, lymphoceles may result from stasis of lymphatic fluid. When the latter develop into bullae, this is referred to as **bullous morphea**. It is more frequently observed in generalized morphea and sclerodermoid or morpheaform GVHD and is rarely a feature of plaque-type morphea. Bullous morphea has to be distinguished from mechanical blisters that may occur centrally within plaques and are secondary to impaired mechanical stability of the dermal–epidermal junction.

Linear Morphea and Parry–Romberg Syndrome

Linear morphea is different from plaque-type morphea, with respect to age of onset, distribution, clinical outcome, and serologies. Morphea *en coup de sabre* (meaning stroke or blow with a single-edged sword) is a term used for linear morphea of the forehead and scalp. Hemifacial atrophy, or Parry–Romberg syndrome, is probably a very severe variant of linear morphea, but it may be a phenotype for more than one entity. There is a progressive loss of subcutaneous fat, but little or no sclerosis (Fig. 44.7). The entire distribution of the trigeminal nerve, including the eye and the tongue, may be affected.

Linear morphea may present initially as a linear, erythematous (inflammatory) streak, but more frequently begins as a harmless-appearing lesion of plaque-type morphea that extends longitudinally as a series of plaques that then join to form a scar-like band (Fig. 44.8). This band may severely impair the mobility of the affected limb. Linear morphea tends to involve the underlying fascia, muscle, and tendons. This leads not only to muscle weakness but also to shortening of the muscles and fascia which then impairs joint mobility. Linear morphea is especially problematic when it extends over joints, as this almost invariably results in a decrease in range of motion and functional impairment[36]. In some patients, involvement is circular rather than linear and results in progressive atrophy of the limb similar to the Parry–Romberg variant of facial morphea. The linear variant can have prolonged periods of quiescence followed by reactivation.

The *en coup de sabre* type of morphea represents linear morphea of the head (Fig. 44.9). It is typically unilateral and extends from the forehead into the frontal scalp. It may start either as a linear streak, which may initially mimic a port-wine birthmark, or as a row of small plaques that coalesce. A paramedian location is most common. Like plaque-type morphea, it may initially be surrounded by a discrete lilac ring that extends longitudinally and may reach the eyebrows, nose, and even the cheeks. As inflammation wanes, a linear, hairless crevice develops that in some patients is sclerotic, while in others appears more atrophic.

Fig. 44.8 Linear morphea of an extremity. A Linear sclerotic band of the arm with both hyper- and hypopigmentation. The majority of patients with linear morphea have unilateral involvement. **B** More inflammatory phase with ulceration in addition to induration. The differential diagnosis includes linear melorheostosis which is often associated with underlying candlewax-like linear hyperostosis. *A, Courtesy Julie V. Schaffer, MD.*

En coup de sabre morphea can also involve the underlying muscles and osseous structures. Rarely, the inflammation and sclerosis progress to involve the meninges and even the brain, creating a potential focus for seizures[37]. Ocular involvement has been reported in up to 15% of juvenile and 25% of adult patients.

Generalized Morphea

Generalized morphea normally begins insidiously on the trunk as plaque-type morphea. While individual lesions are indistinguishable in these two forms, in generalized morphea they do not stop expanding. Just as in the diffuse form of SSc, multiple plaques rapidly coalesce and can affect nearly the entire trunk, often only sparing the areolae and nipples (Fig. 44.10). The sclerosis may involve the extremities down to the hands (presenting initially as puffy edema). As the cutaneous sclerosis progresses, it may result in disabling constrictions that even cause difficulty in breathing due to impaired thorax mobility and inflammation of the intercostal muscles. Although an aggressive therapeutic approach is recommended, the disease is usually persistent given its often limited response to treatment.

Downloaded for Anonymous User (n/a) at Egyptian Knowledge Bank from ClinicalKey.com by Elsevier on March 10, 2024. For personal use only. No other uses without permission. Copyright ©2024. Elsevier Inc. All rights reserved.

Fig. 44.9 Morphea *en coup de sabre*. On the forehead, the linear band(s) of sclerosis and atrophy are usually paramedian (rather than midline). **A** Both hyper- and hypopigmentation are present as well as subtle depression. **B** An obviously depressed, sclerotic, hypopigmented linear band. **C** Scarring alopecia develops when there is involvement of scalp; "lonely hairs" are also seen in other forms of scarring alopecia. **D** Note the prominent veins and loss of the medial eyebrow. Progression to Parry–Romberg syndrome would be a concern.

Fig. 44.10 Generalized morphea. A Multiple hyperpigmented plaques on the trunk that are becoming confluent. **B** Circumferential involvement with sparing of the central portion of the breast is a classic distribution pattern. *B, Courtesy Luis Requena, MD.*

Downloaded for Anonymous User (n/a) at Egyptian Knowledge Bank from ClinicalKey.com by Elsevier on March 10, 2024. For personal use only. No other uses without permission. Copyright ©2024. Elsevier Inc. All rights reserved.

Fig. 44.11 Extensive linear morphea of the right leg leading to hypoplasia. In addition to marked hypoplasia, there is induration and a flexion contracture of the knee.

Morphea in Childhood

Approximately 20% of individuals with morphea are children and teenagers. The female-to-male ratio for plaque-type morphea in this age group is about 2:1, with a mean age at disease onset of 7 years[38]. In two-thirds of patients with linear morphea, disease onset is prior to age 18 years, providing an explanation for the possibility of growth retardation of the affected limb. Thus, if left untreated, linear morphea may result not only in decreased range of motion of joints but also in permanent limb asymmetry from unilateral hypoplasia (Fig. 44.11).

Pansclerotic morphea, also referred to as disabling pansclerotic morphea of children, is similar to generalized morphea of the adult. It usually starts before 14 years of age and tends to cause lifelong severe disability due to persistent atrophy of the underlying muscles and contractures of the involved joints. The disease tends to extend from the trunk to the hands and feet. Periodontal atrophy may occur, but there is only slight involvement of the esophagus and lung. Distinction from SSc may prove challenging.

Importantly, in a large multicenter study of children with morphea, 22% had extracutaneous findings that were primarily articular (11%), neurologic (4%), and ocular (2%)[38]. The latter two findings were seen primarily in those with linear morphea of the head or Parry–Romberg syndrome, i.e., 85% of affected patients had these two variants.

LABORATORY FINDINGS

Laboratory abnormalities are not a prominent feature of morphea, except for generalized and linear morphea. The ESR and serum protein levels are usually normal, but eosinophilia may occur, especially during early active phases of the disease. High titers of ANA or antibodies to ssDNA and histones can be detected in 40%–80% of patients with linear and generalized morphea, but are uncommon in adults with plaque-type morphea (see above). Approximately 40% of children and adolescents with morphea have elevated ANA titers[38].

PATHOLOGY

The histopathology of morphea depends on two factors: the stage and area of the lesion sampled (inflammatory margin or central sclerosis) and the depth to which the disease extends. In most situations, morphologic changes are best seen at the border between the dermis and subcutaneous fat. Specimens for histopathology must include subcutaneous fat and it is important to note whether the biopsy specimen is taken from the inflammatory border or from the fibrotic center.

At the inflammatory border, vascular changes are relatively discrete by light microscopy. Vessel walls show endothelial swelling and edema. Capillaries and small arterioles are surrounded by an infiltrate that contains primarily $CD4^+$ T cells and sometimes eosinophils, plasma cells, and mast cells (Fig. 44.12A).

In later stages, the inflammatory infiltrate wanes and ultimately disappears completely, except in some areas of the subcutaneous fat. The epidermis is basically normal in appearance, but the rete ridges may be diminished, leaving a flattened dermal–epidermal junction. Edema is no longer visible in the dermis and upper subcutis. Capillaries and small vessels are significantly reduced in number, and homogeneous collagen bundles with decreased space between the bundles replace most structures. At this stage, collagen bundles in the reticular dermis appear densely packed, as evidenced by a more intense eosinophilic staining, and are aligned parallel to the dermal–epidermal junction (Fig. 44.12B). Eccrine glands appear atrophic and "trapped" within the thickened dermis. The underlying subcutis is homogenized and hyalinized.

Deep morphea affects primarily the deep subcutaneous tissue. Following the inflammatory phase, extensive sclerosis and hyalinization extend into the underlying fascia. Involvement of the underlying fascia is obligatory in deep morphea and is also frequently observed in linear and generalized types of morphea. In these patients, the fascia and even the underlying muscle (frequently vacuolated) are involved in the process of progressive sclerosis, characterized by replacement of the differentiated tissue by collagen bundles.

MORPHEAFORM (AND SCLERODERMOID) INFLAMMATORY SYNDROMES

Some disorders that are characterized by acrosclerosis and Raynaud phenomenon (e.g. sclerosis secondary to exposure to bleomycin, vinyl chloride, or epoxy resin) have a clinical presentation similar to lcSSc (i.e. sclerodermoid or pseudoscleroderma), while others present with circumscribed plaques similar to morphea (i.e. morpheaform). The former are discussed in Chapter 43 and the latter are discussed below and presented in Table 44.2. There are also clinical disorders that may have either type of clinical presentation, such as chronic GVHD.

While a variety of inflammatory diseases ultimately lead to superficial or deep sclerosis of the skin, their exact relationship to morphea is enigmatic. Some of these diseases are preceded by or associated with eosinophilia in blood or tissue. Infiltration by eosinophils may be of unknown etiology, as in eosinophilic fasciitis, or it may reflect an immune reaction to a defined toxic insult or antigenic stimulus, as in the L-tryptophan syndrome (eosinophilia–myalgia syndrome), toxic oil syndrome, or GVHD following hematopoietic stem cell transplantation (HSCT). Lastly, since certain exogenous drugs or chemicals, endogenous metabolites, or X-irradiation induce sclerosis at the site of tissue injury in only a subset of individuals, this suggests that unique metabolic events and innate or adaptive immune responses to these compounds determine the individual's susceptibility to develop sclerosis[2].

- **Lipodermatosclerosis**. Chronic venous insufficiency, along with chronic hypoxia, leads to sclerosis, most commonly on the lower extremities. This entity is discussed in Chapter 100.
- **Injections of vitamin K_1 (Texier disease)**. Rarely, injection of oil-soluble vitamin K_1 causes a strictly localized eosinophilic fasciitis that is indistinguishable from deep morphea. It may ultimately resolve with dermal and/or subcutaneous atrophy.
- **Vaccination-associated morphea**. Development of plaque-type or deep morphea has been described in children and adults at intramuscular vaccination sites. Given the limited number of case reports, it is uncertain whether the antigens, the adjuvants, or the injection trauma trigger the inflammatory fibrosis[39].
- **Paraffin and silicone injections or implants**. It is suspected that leakage of silicone implants and injection of silicone or liquid paraffin during reconstructive surgery and cosmetic soft tissue augmentation may cause chronic inflammation that results in localized morphea-like sclerosis. The belief that these substances

Downloaded for Anonymous User (n/a) at Egyptian Knowledge Bank from ClinicalKey.com by Elsevier on March 10, 2024. For personal use only. No other uses without permission. Copyright ©2024. Elsevier Inc. All rights reserved.

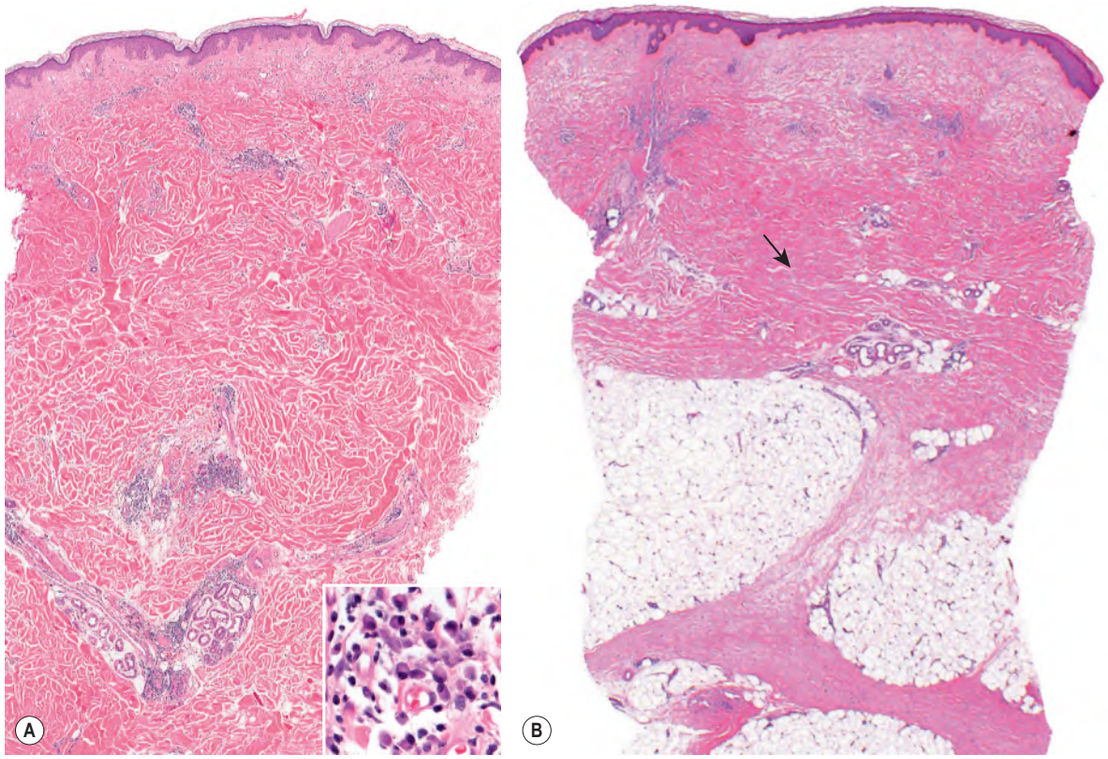

Fig. 44.12 Morphea – histopathologic features. A Overview with thickening of the dermis and perivascular and periecrine infiltrates of lymphocytes and plasma cells (inset). These changes can be seen in the inflammatory border. **B** Advanced sclerosis of the entire dermis extending into the fat with thickened collagen bundles and "trapped" eccrine glands (arrow). This corresponds to the areas of induration within the plaque. *A, Courtesy Lorenzo Cerroni, MD.*

can trigger systemic diseases such as SSc, eosinophilic fasciitis, or mixed connective tissue disease was not substantiated when meta-analyses were performed.

- **Porphyrias**. In adults, porphyria cutanea tarda can lead to morphea-like sclerosis in UV-exposed sites, such as the face, hairless scalp, dorsal aspects of the hands, and the upper chest. Histopathology and electron microscopy findings may resemble morphea except for the presence of PAS-positive deposits around dermal blood vessels. Other rare forms of porphyria can also lead to scarring in UV-exposed sites (see Ch. 49).
- **Radiation-induced morphea**. This disorder is characterized by marked sclerosis, erythema, and pigmentary changes occurring within the radiation field or even beyond it (Fig. 44.13). The incidence of radiation-induced morphea is about 1 in 500 patients and it is seen primarily in patients treated for breast carcinoma. Predictive risk factors for the development of radiation-induced morphea are unknown and it can present several years after radiation therapy. In addition to the changes of radiation dermatitis, histopathology demonstrates perivascular and subcutaneous inflammation together with dermal fibrosis and collagen deposition.
- **Nephrogenic systemic fibrosis**. This entity is discussed in detail in Chapter 43.
- **Chronic GVHD**. Patients with chronic GVHD may develop lesions that resemble morphea and lichen sclerosus as well as eosinophilic fasciitis (see Ch. 52).

DIFFERENTIAL DIAGNOSIS

In addition to the other morpheaform and sclerodermoid conditions discussed above, the most important entity in the differential diagnosis is SSc (see Ch. 43). Asymmetric skin involvement as well as the absence of Raynaud phenomenon and lung or esophageal involvement are characteristic features of morphea. The other common considerations are lichen sclerosus and keloids; however, the former can coexist with morphea. Dupuytren contracture and camptodactyly, a benign ulnar deviation of the fourth and fifth finger, can be clinically distinguished from linear morphea.

Scleredema leads to diffuse woody induration, primarily of the upper back and neck. Symmetric tightness and induration of acral skin can be seen in insulin-dependent diabetics with cheiroarthropathy, also referred to as waxy skin and stiff joints. In children, progeria and premature aging syndromes need to be distinguished from Parry–Romberg syndrome, but the latter is unilateral, as is silent sinus syndrome. Additional entities in the sclerodermoid differential diagnosis (e.g. scleromyxedema) are listed in Table 43.7.

TREATMENT

Various therapeutic modalities have been described for morphea, although quality evidence in support of many of these therapies has been limited[40]. In addition, there has been a lack of standardized outcome measures for assessing the efficacy of various therapies. However, the localized scleroderma cutaneous assessment tool (LoSCAT) is gaining recognition as a valid and reproducible index for disease activity and damage in morphea[41]. Radiologic imaging (e.g. ultrasound, MRI) may also provide useful information[41].

The major therapies for morphea include topical medications, phototherapy, systemic immunosuppressants, and physical/occupational therapy (Table 44.3). Several factors, including level of disease activity, subtype of morphea, depth of involvement, location and extent of disease, and degree of current or potential functional impairment or disfigurement, play a role in determining the most appropriate treatment.

Therapies are most effective when there is active disease (e.g. inflamed and expanding patches and plaques), whereas inactive disease (e.g. fixed sclerotic plaques) is less likely to respond. Plaque-type morphea

Downloaded for Anonymous User (n/a) at Egyptian Knowledge Bank from ClinicalKey.com by Elsevier on March 10, 2024. For personal use only. No other uses without permission. Copyright ©2024. Elsevier Inc. All rights reserved.

DIFFERENTIAL DIAGNOSIS OF MORPHEAFORM SKIN LESIONS
Morphea (plaque-type, linear, generalized* or deep*)
Chronic graft-versus-host disease*
Lichen sclerosus (may coexist with morphea)
Lipodermatosclerosis*
Sclerosis at injection sites
• Vitamin K_1 (Texier disease) or vitamin B_{12}
• Silicone or paraffin implants
• Interferon-β
• Glatiramer
• Enfuvirtide
• Bleomycin (intralesional therapy)
• Opioids (e.g. pentazocine, ketobemidone, methadone)
• Vaccinations
Medications and chemical/toxin exposures†
• Immune checkpoint inhibitors
• Aromatic/chlorinated hydrocarbons (e.g. benzene or toluene at sites of contact with skin)*
• Nephrogenic systemic fibrosis (induced by gadolinium-containing contrast media)*
• Toxic oil syndrome (historical)*
Radiation-induced morphea
Porphyria (porphyria cutanea tarda, hepatoerythropoietic porphyria, congenital erythropoietic porphyria)*
Muckle–Wells syndrome
Winchester syndrome*
Stiff skin syndrome*
Linear melorheostosis
Complex regional pain syndrome*
Morpheaform sarcoidosis
Sclerosing congenital melanocytic nevus
Paraneoplastic scleroderma-like syndrome*
Cutaneous metastases (e.g. carcinoma *en cuirasse*)
*Can overlap with sclerodermoid disorders, which are outlined in Table 43.7; in particular, deep morphea and eosinophilic fasciitis may have a similar appearance. †Systemic medications for which there have also been reports of an association with morpheaform lesions include bleomycin, taxanes (e.g. paclitaxel, docetaxel), bromocriptine, ethosuximide, valproic acid, appetite suppressants, and penicillamine.

Table 44.2 Differential diagnosis of morpheaform skin lesions.

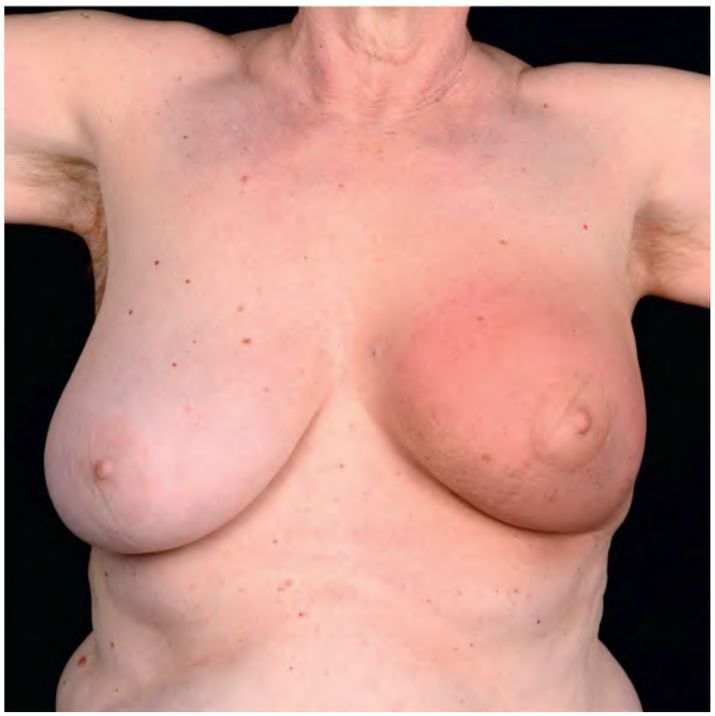

Fig 44.13 Radiation-induced morphea. Erythema and induration of the left breast. *Courtesy Department of Dermatology, Medical University of Graz.*

APPROACH TO THE TREATMENT OF MORPHEA	
Morphea variant	**Treatment**
Plaque–type (circumscribed)	*First-line** • Topical class I CS, daily–twice daily • Intradermal CS (e.g. triamcinolone acetonide 5–10 mg/mL) every 4–6 weeks into active rim • Tacrolimus 0.1% ointment, twice daily *Second-line* • Topical vitamin D analogue (calcipotriene [calcipotriol]) under occlusion ± class I topical CS • Lesion-limited phototherapy† *Third-line (or if lesions spreading, unstable)* • Generalized phototherapy† • Weekly methotrexate‡ • Topical crisaborole 2% ointment for steroid-refractory plaque *Refractory, rapidly progressive, or deep variant* • Weekly methotrexate‡ ± systemic CS¶ • CS-sparing agents (e.g. mycophenolate mofetil, JAK inhibitors [e.g. tofacitinib])
Linear	**Deep variant, facial involvement, crossing joints** *First-line** • Weekly methotrexate‡ ± systemic CS¶ *Second-line* • CS-sparing agents (e.g. mycophenolate mofetil, JAK inhibitors, tocalizumab) **Superficial variant, not involving face or crossing joints** • Phototherapy†
Generalized	*First-line** • Phototherapy† (if superficial and without joint contractures) • Weekly methotrexate‡ ± systemic CS¶ *Second-line* • CS-sparing agents (e.g. mycophenolate mofetil, JAK inhibitors [e.g. tofacitinib, baricitinib], tocalizumab)
Pansclerotic	See systemic therapies for generalized morphea
*If not improved after ~8 to 10 weeks, progress to next line of therapy. †Phototherapy choice based on local availability (UVA1, BB-UVA, PUVA), with preference for UVA1 if available; NB-UVB may be considered for limited, superficial plaque-type disease. ‡Weekly methotrexate doses, either orally or subcutaneously: adults, 15–25 mg/week; children, 0.3–0.5 mg/kg/week. ¶Especially for early/progressive lesions; pulsed dosing (e.g. intravenous methylprednisolone 1000 mg/day for three consecutive days per month, with a pediatric dose of 30 mg/kg/day in those ≤ 33 kg) favored over daily dosing (e.g. oral prednisone 1 mg/kg/day).	

Table 44.3 Approach to the treatment of morphea. Treatment is most effective in active, inflammatory lesions. Systemic therapy should be instituted if: (1) progression or risk of functional impairment (e.g. decreased range of motion of joints, involvement across joints) or significant disfigurement (e.g. linear facial morphea); (2) deep morphea (e.g. subcutaneous, fascia, muscles). Systemic retinoids (e.g. acitretin 10–50 mg/day), apremilast (30 mg twice daily), abatacept, and hydroxychloroquine (200–400 mg/day) are additional therapies. CS, corticosteroids.

with limited body surface area involvement can often be managed with topical therapies while generalized or extensive disease responds best to phototherapy or systemic medications. Active deep morphea with involvement of the subcutaneous tissue, fascia, or muscles as well as morphea with the potential for functional impairment (e.g. linear morphea overlying joints) or significant disfigurement (e.g. facial involvement) should be managed aggressively with systemic immunosuppressants. In addition, patients at risk for functional impairment (e.g. joint contractures, loss of mobility) should be referred to physical and occupational therapists before the onset of such complications.

If persistent contractures do develop, reconstructive surgery may be required. Surgical revision can be offered for inactive linear or *en coup de sabre* morphea. Autologous fat transplantation has been used successfully for Parry–Romberg syndrome and injection of hyaluronic acid fillers, with or without fractional laser ablation, to correct facial morphea has been reported[42]. Finally, patients with extracutaneous involvement may require additional evaluation and management, such as rheumatologic referral for arthritis or synovitis. Patients with

Downloaded for Anonymous User (n/a) at Egyptian Knowledge Bank from ClinicalKey.com by Elsevier on March 10, 2024. For personal use only. No other uses without permission. Copyright ©2024. Elsevier Inc. All rights reserved.

morphea that involves the head are at risk for ocular and/or neurologic complications and, when indicated, referred to ophthalmology and neurology, respectively.

Phototherapy

Phototherapy for morphea was first described in 1994[43], and since then, efficacy has been confirmed by more than 30 publications[44,45] and was recently supported by an open label controlled study[46]. Various phototherapy modalities have been used, including UVA1, broadband UVA (BB-UVA), PUVA, and narrowband UVB (NB-UVB). When available, UVA1 has become the phototherapy of choice, followed by BB-UVA and PUVA. NB-UVB, because of its shallower depth of penetration, may be beneficial for superficial morphea but is less effective for deeper morphea. Treatment can be lesion-directed when there is a limited number of plaques or administered to the majority of the skin surface. The efficacy of phototherapy is thought to be due to immunomodulatory effects as well as upregulation of matrix metalloproteinases that stimulate collagen breakdown. Patients may also benefit from phototherapy plus low-dose systemic retinoids as this combination has led to improvement of sclerodermoid GVHD and plaque-type morphea[18,47].

Due to the nature of phototherapy, placebo-controlled studies have not been performed. Nonetheless, little doubt exists as to the efficacy of this therapy, as untreated morphea normally progresses over 3–5 years and then regresses very slowly over several years. More rapid spontaneous improvement only occurs in a small minority of patients[3]. The clinical course is definitely different in patients receiving phototherapy. Following 30–36 treatments of bath PUVA therapy (at slightly suberythematous doses) or UVA1 (30–60 J/cm^2), morphea resolves or markedly improves in at least 60% of patients[48,49] (Fig. 44.14). Further advantages of phototherapy, and especially UVA1, include clinical improvement in all skin types[50] and sustained remissions. Recurrence of morphea plaques after successful phototherapy has been reported, but primarily in patients with a prolonged period of disease prior to initiation of phototherapy. The dose of UVA1 phototherapy (medium versus high) does not appear to correlate with risk of recurrence[51].

The ideal dose for UVA1 therapy has been debated. Most initial studies were performed with either low (20–30 J/cm^2) or medium doses (40–70 J/cm^2) of UVA1 and reported similar efficacy. A study that utilized 20 MHz ultrasound rather than clinical assessment of morphea lesions reported a better response with medium-dose (70 J/cm^2) than with low-dose (20 J/cm^2) UVA1[52]. In agreement with these reports, we have observed that 36 treatments with either 30 J/cm^2 or 50–60 J/cm^2 of UVA1 markedly improves morphea in the majority of patients[48]. Importantly, in responding patients, lesions of morphea continue to improve beyond the end of the therapy. Thus, therapy can be terminated after 36 treatments, even if the sclerosis has not yet completely resolved. The only exception appears to be linear morphea, which may require up to 60 treatments.

Fig. 44.14 Phototherapy for morphea. Disseminated morphea on the trunk, with sparing of the central portions of the breasts. Before (**A**) and after (**B**) PUVA bath photochemotherapy.

Systemic Therapies

Indications for systemic therapies are outlined above and in Table 44.3. For decades, methotrexate, either alone or in combination with systemic corticosteroids, has represented a first-line treatment[53–55]. Systemic corticosteroids are often added for severe involvement or when more rapid control of the disease is desired[56–58]. Typically, the methotrexate is continued for at least 12 months and tapering is not begun until at least 6–12 months after the disease is inactive. Tapering of systemic corticosteroids (over several months) usually occurs sooner, once the disease is no longer active.

Recent data from retrospective cohort and longitudinal studies suggest that mycophenolate mofetil (MMF) is also beneficial and well tolerated in patients with severe morphea, even in those with a history of previously ineffective treatments[59,60]. MMF is usually the next line of treatment should methotrexate +/– corticosteroids fail or be contraindicated. Efficacy data for other systemic agents are even more limited. In small case series, JAK inhibitors (e.g. tofacitinib, baricitinib) led to improvement in patients with recalcitrant morphea or eosinophilic fasciitis[61]. Additional reported therapies include hydroxychloroquine[62] and systemic retinoids (acitretin, isotretinoin)[17,18,63,64]. Of note, vitamin A derivatives have antifibrotic effects and can modulate collagen metabolism[65].

In case series and reports, improvement has been observed with tocilizumab, which blocks the IL-6R, including for pansclerotic morphea in children[66], as well as abatacept, a CTLA4 fusion protein that inhibits T cell activation[67]. A placebo-controlled, multi-center trial with dupilumab, which blocks the interaction of the profibrotic cytokines IL-4 and IL-13 with IL-4Rα, is currently underway. Lastly, a novel approach based upon genetically modified autologous fibroblasts that express metalloproteinase-1 (MMP-1) has not progressed beyond phase I/II trial status.

LICHEN SCLEROSUS

Synonyms/site-specific names: ▪ Lichen sclerosus et atrophicus ▪ Kraurosis vulvae ▪ Balanitis xerotica obliterans (lichen sclerosus of the penis)

Key features

- Sclerotic, ivory-white, flat papules and plaques with epidermal atrophy and, in extramucosal sites, follicular plugging
- Most commonly affects female or male genitalia, less often extragenital skin
- May cause scarring of the vaginal introitus or phimosis
- Severe pruritus may occur
- No systemic manifestations

INTRODUCTION

Lichen sclerosus (LS) is a clinically distinct inflammatory disease, primarily of the superficial dermis or submucosa, that leads to ivory-white scar-like atrophy. Extragenital LS may itch and be cosmetically disturbing whereas genital LS causes both dryness and severe, persistent pruritus, and it often leads to progressive atrophy and functional impairment. Phimosis or scarring of the vaginal introitus are the most frequent complications. If left untreated, ~4% of patients with vulvar LS may develop differentiated vulvar intraepithelial neoplasia (VIN) or squamous cell carcinoma (SCC)[68].

Downloaded for Anonymous User (n/a) at Egyptian Knowledge Bank from ClinicalKey.com by Elsevier on March 10, 2024. For personal use only. No other uses without permission. Copyright ©2024. Elsevier Inc. All rights reserved.

HISTORY

François Henri Hallopeau's report on a "lichen plan atrophique" in 1887 is considered to be the first description of LS. The typical histopathologic changes of lichen sclerosus et atrophicus were published by Ferdinand Jean Darier in 1892. Unna, Westberg, von Zumbusch, and others elucidated the clinical features of LS in various case reports[69]. This contributed to the panoply of terms, such as white spot disease or lichen albus, an aspect that complicates any literature survey. Lichen sclerosus in the genital area was first described in women by August Breisky as kraurosis vulvae and 40 years later in men by Alfred Stühmer as balanitis xerotica obliterans. Today, lichen sclerosus, the term proposed by the International Society for the Study of Vulvar Disease, is used most frequently[70,71].

EPIDEMIOLOGY

Lichen sclerosus is relatively uncommon, although the exact prevalence is unknown. It occurs at all ages with a similar incidence in all races; the reported female-to-male ratio varies widely, depending upon the study, from 10:1 to 1:1[70,71]. In both sexes, the anogenital area is affected in ~85% of patients, but the best epidemiologic studies concentrate on vulvar disease.

Studies in adult patients suggest that LS is one of the most common causes of symptomatic vulvar disease. In two large series, LS was diagnosed in 13% to 19% of patients presenting with symptomatic vulvar disease. In women, the peak incidence is during the fifth and sixth decades, and a second peak occurs in girls between 8 and 13 years of age. Among prepubertal girls with vulvar disease, the relative frequency of LS is similar to that in adults. Extragenital LS is rare in children. In boys and men, LS frequently leads to phimosis (seen in 14 of 100 prepubertal boys undergoing circumcision for phimosis). Of 357 male patients attending a dermatology clinic because of genital skin disease, 14% had LS[72].

A recent retrospective analysis demonstrated a high prevalence of LS in patients with plaque-type morphea and generalized morphea[73]. This coexistence suggests either a common trigger or a common susceptibility factor for both diseases.

PATHOGENESIS

As in most inflammatory diseases, genetic predisposition contributes to the development of LS, as it may be found in monozygotic and fraternal twins. In addition, association with the MHC class II antigen HLA-DQ7 was observed in a relatively large study. The existence of a relevant susceptibility gene for sclerosis within this region of the MHC is underlined by the finding that the same region is associated with a greater risk of organ-specific autoimmune diseases. Even though inflammation seems essential for initiation and progression of LS, the mechanisms leading to subsequent sclerosis remain speculative. Increased production of IL-6, TNF, and collagen (types I, III, and V) is thought to promote the sclerosis[74].

Perhaps with the exception of autoantibodies against extracellular matrix protein 1 (ECM-1), no specific immunologic parameters have been identified in patients' sera that clearly correlate with either risk of disease or disease activity. IgG autoantibodies against ECM-1 are found in 80% of patients with LS[75]. Moreover, in female patients with LS, there is a higher prevalence of autoimmune diseases (especially autoimmune thyroid disease) and ANA positivity than in male patients with LS[76].

Oxidative stress may also play a role in the pathogenesis of LS, based upon analysis of lesional skin that showed lipid peroxidation of epidermal basal cell layers, oxidative DNA damage, and oxidative protein damage.

CLINICAL FEATURES

Lichen sclerosus most frequently affects the anogenital region, and less often extragenital skin. Lichen sclerosus of the oral cavity, palms, or soles is rare. Intraorally, bluish-white papules up to 5 mm in diameter may occur on the buccal mucosa or under the tongue. They can lead to superficial scar-like atrophy or erosions.

Extragenital LS normally does not cause symptoms except for dryness and associated pruritus. Lesions favor the trunk (Fig. 44.15) and the proximal extremities. More specific predilection sites include the neck, shoulders, flexor surfaces of the wrists, and sites of physical trauma or continuous pressure (e.g. the shoulder or hip). The periorbital area and scalp are rarely affected.

It is unusual to see extragenital disease during its early phases when single lesions begin as polygonal, bluish-white, shiny, slightly elevated, interfollicular papules. Over time, these papules often enlarge or coalesce into larger plaques. Most patients present with slightly sclerotic, scar-like papules and plaques that are usually ivory in color and have a shiny and/or wrinkled surface. Occasionally, lesions have a pink or light violet hue. At sites of continuous pressure, the surface may acquire a parchment-like appearance.

In more advanced stages, telangiectasias or follicular plugging can be seen (Fig. 44.16A). The flattened interface between the epidermis and dermis results in fragility of the dermal–epidermal junction. As a result, LS is occasionally complicated by the development of bullae that tend to become hemorrhagic (Fig. 44.16B).

In women, the vulva and the perianal region are commonly involved, often in a figure-of-eight configuration (see Ch. 73). Although the disease may be symptom-free, it frequently causes severe pruritus and soreness. These symptoms may be considerable and lead to dysuria, dyspareunia, or pain upon defecation (often manifesting as constipation in children). As a result, quality of life can be adversely affected, including in children and adolescents[77,78].

Vulvar LS often begins as a slightly elevated, sharply demarcated area of erythema, which can be slightly eroded. Over time, the involved skin becomes shiny, hypopigmented, and sclerotic, and fissures may develop, especially in the perineum (Fig. 44.17). When progressive, associated scarring can lead to burying of the clitoris and fusion of the

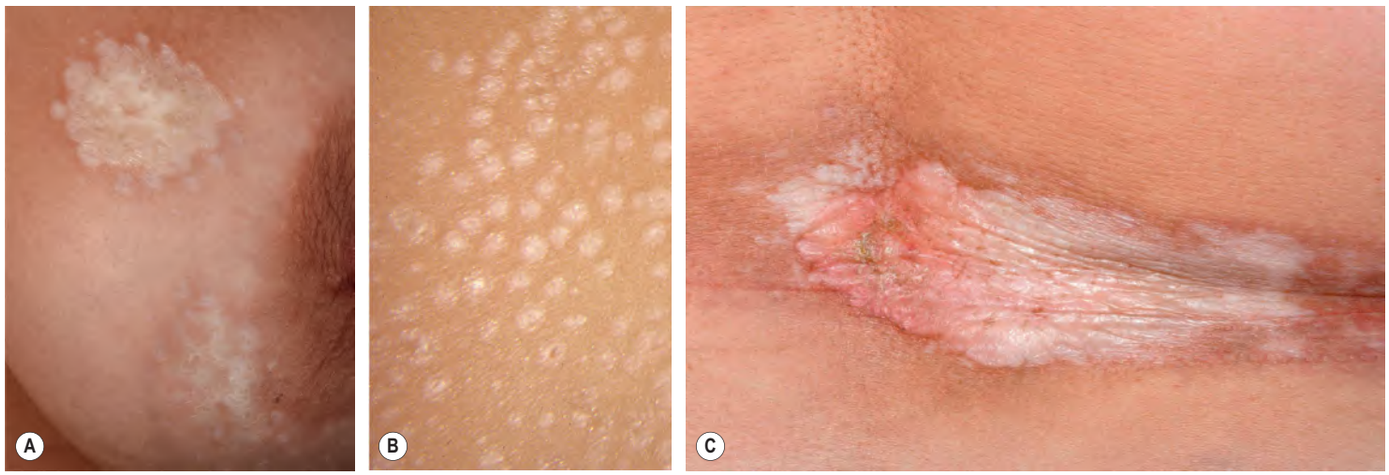

Fig. 44.15 Lichen sclerosus. A Shiny, ivory-colored plaques on the breast with several guttate satellite lesions. **B** In some patients, only guttate lesions are present. **C** Large ivory-colored, shiny plaque on the waistline, a site of persistent pressure. *B, Courtesy Louis A. Fragola, Jr, MD.*

Downloaded for Anonymous User (n/a) at Egyptian Knowledge Bank from ClinicalKey.com by Elsevier on March 10, 2024. For personal use only. No other uses without permission. Copyright ©2024. Elsevier Inc. All rights reserved.

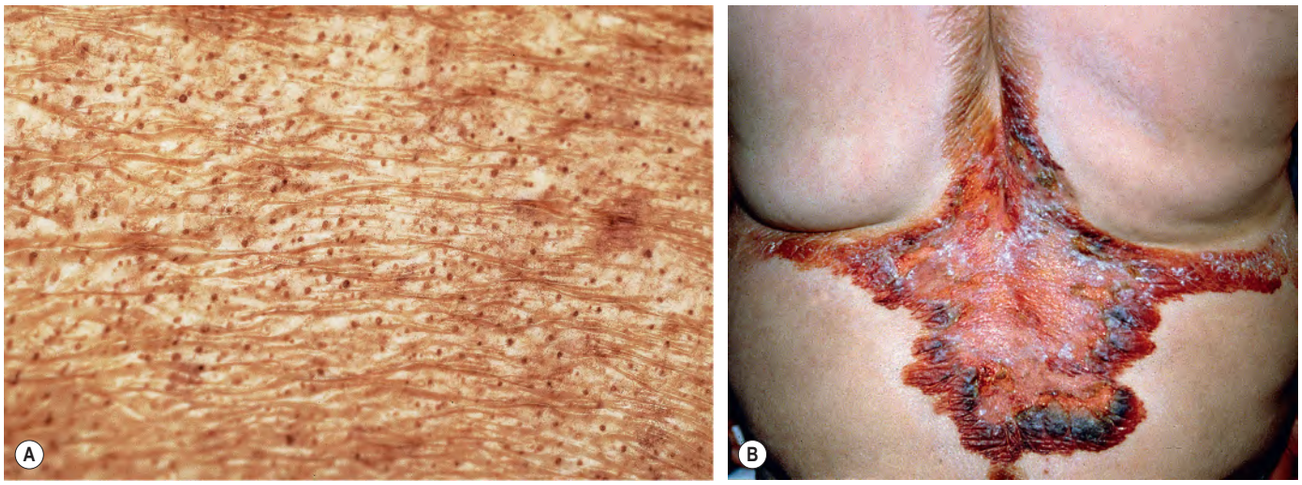

Fig. 44.16 Lichen sclerosus. A Follicular plugging in a plaque of lichen sclerosus on the back of a patient with chronic GVHD. **B** Hemorrhagic bullae primarily at the periphery of a large plaque on the back. *A, Courtesy Jean L. Bolognia, MD; B, Courtesy Luis Requena, MD.*

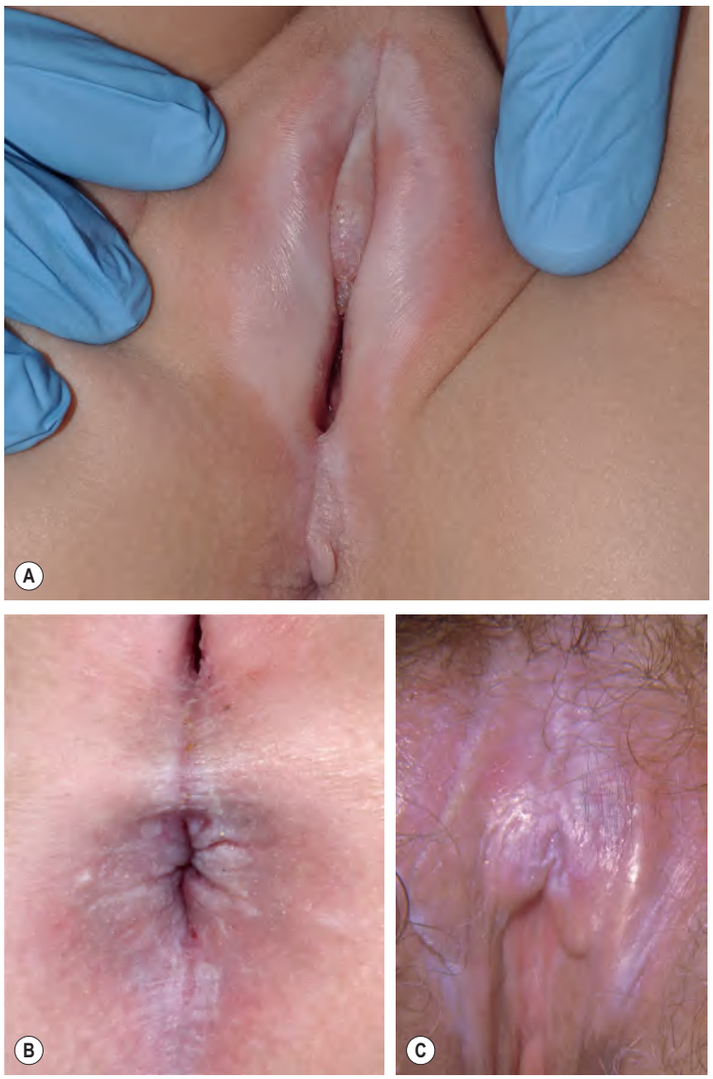

Fig. 44.17 Anogenital lichen sclerosus. A Characteristic vulvar, perineal, and perianal involvement in a child. Symmetric ivory-colored, shiny plaques with a thin pink peripheral rim are seen; a perianal pyramidal protrusion is also present. **B** Perianal lichen sclerosus in which the hypopigmented plaques are accompanied by a linear erosion (skin tear) at 6 o'clock and central fissuring of the perineum. **C** Involvement of the clitoral hood and clitoris as well as fusion of the left labia minora and labia majora. *A, Courtesy A. Hernández-Martín, MD; C, Courtesy Louis A. Fragola, Jr, MD.*

Fig. 44.18 Lichen sclerosus of the penis (balanitis xerotica obliterans). Note the ivory color, erosion, and scarring.

labia minora to the labia majora, and when untreated, an increased risk of malignancy[68]. With severe disease, loss of the labia minora and significant narrowing of the introitus can occur. Sexual intercourse may become impossible. In general, LS does not worsen during pregnancy and when treated successfully, vaginal delivery is possible without an increased incidence of perineal tears and episiotomies (compared with healthy control populations)[79].

Areas of purpura often develop within lesions of anogenital LS and can actually aid in the clinical diagnosis (see Fig. 73.3). However, the hemorrhage combined with erosions may be misdiagnosed as sexual abuse (see Ch. 90). A careful history and clinical examination, along with histologic confirmation when needed, can assist in establishing the diagnosis.

In boys and men, acquired phimosis or recurrent balanitis are the primary presenting features, and perianal involvement is rare. Itching and soreness are common. On the glans and the inner aspect of the foreskin, LS starts as sharply demarcated, sometimes slightly blue–red lesions, occasionally with erosions. This inflammation tends to evolve into an atrophic white sclerotic scar (Fig. 44.18). The constriction may cause pain on erection and, at advanced stages, dysuria and urinary obstruction. If the foreskin is affected in uncircumcised male patients, LS invariably leads to phimosis (difficulty in retracting the foreskin to uncover the glans), with the additional risk of paraphimosis (when a foreskin is retracted behind the glans and cannot be returned to its original position); the latter represents a urologic emergency. Many boys and men first present when the phimosis impairs repositioning of the foreskin;

Downloaded for Anonymous User (n/a) at Egyptian Knowledge Bank from ClinicalKey.com by Elsevier on March 10, 2024. For personal use only. No other uses without permission. Copyright ©2024. Elsevier Inc. All rights reserved.

in these situations, diagnosis depends on histology. With progression, poorly healing ulcers of the glans can develop. While circumcision is clearly a first-line therapy, LS may recur at the site of a circumcision.

A continuing debate is whether genital LS is a precancerous condition. Interpretation and comparison of the data are complicated by at least two factors: some of the patients reported as developing cancer had previously received X-ray therapy for the disease or had previous dysplasia due to human papillomavirus (HPV) infection. It is therefore very difficult to perform a useful meta-analysis based on existing data. Some data suggest that genital LS is not intrinsically precancerous, but a recent prospective cohort study of 507 women with vulvar LS noted the development of SCC or VIN in 5% of patients partially compliant with topical corticosteroid treatment and in none of the compliant patients, with a mean follow-up of 4.7 years[68,70,71,80]. Whether the microRNA signature will assist in identifying those patients at increased risk of SCC remains to be determined[80a].

Lentigines and melanocytic nevi can arise within areas of LS, primarily genital LS; histologically they may resemble persistent (recurrent) melanocytic nevi and therefore be confused with melanoma[81].

PATHOLOGY

Lichen sclerosus has a specific histologic pattern that is seen in all age groups[82]. Initially, superficial dermal edema is associated with a band-like lymphocytic infiltrate (Fig. 44.19A). The epidermis is thinned, with orthohyperkeratosis and vacuolar degeneration of the basal layer. Hyperkeratosis is especially pronounced at follicular openings and may lead to plugging. Vacuolar degeneration of the basal layer and flattening of the rete ridges predispose to the development of blisters, which may become hemorrhagic. The most important changes are found in the superficial dermis, where the pale staining reflects edema initially and then homogenized dermal collagen (Fig. 44.19B). Loss of elastic fibers is typical for LS and is not observed in morphea. Subepidermal clefting and hemorrhage within the homogenized papillary dermis is frequently observed.

During the early phases, the inflammatory infiltrate is especially pronounced along the zone of hyalinization and consists of lymphocytes ($CD3^+$, $CD4^+$, $CD8^+$), macrophages, and mast cells. In older lesions, the mononuclear infiltrate is reduced and sparse, and patchy islands of mononuclear cells are dispersed within the hyalinized dermis. Ultrastructural studies reveal shortened collagen fibers.

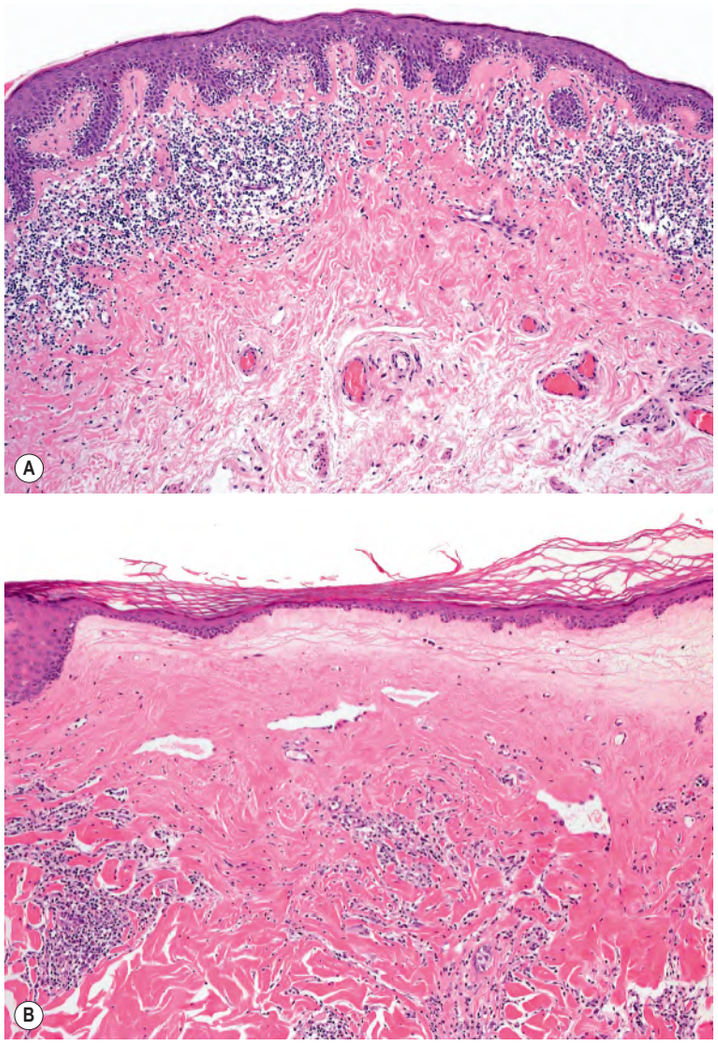

Fig. 44.19 Lichen sclerosus – histopathologic features. A Early lesion with band-like infiltrate of lymphocytes in the upper dermis and vacuolar change at the dermal–epidermal junction. Mild homogenization of the papillary dermis is present. **B** Late lesion with orthohyperkeratosis, thinning of the epidermis, and homogenization of the upper dermis. There is also hyalinization and sclerosis of the papillary dermis, telangiectasias, and an interstitial lymphocytic infiltrate. *Courtesy Lorenzo Cerroni, MD.*

DIFFERENTIAL DIAGNOSIS

The most important entity in the differential diagnosis of extragenital LS is morphea, and in the case of genital LS in girls and boys, sexual abuse. However, morphea and LS may coexist in the same patient. In adults, genital LS may mimic erosive lichen planus, mucous membrane pemphigoid, or erythroplasia of Queyrat (see Ch. 73). Distinction often requires histologic examination. Biopsies may also be needed to exclude associated differentiated VIN or invasive SCC. Histologically, LS-associated pseudoepitheliomatous hyperplasia has to be distinguished from SCC. A past history of allogeneic HSCT points to chronic GVHD that may be clinically and histologically indistinguishable from morphea or LS (see Fig. 44.16A).

TREATMENT

Genital Lichen Sclerosus

Identification, early treatment, and ongoing maintenance therapy of *genital* LS is recommended, with the goals of relieving symptoms (e.g. pruritus), reversing skin changes (e.g. hyperkeratosis), and preventing the development of scarring, adhesions, and SCC[68,83]. Table 73.1 outlines a detailed approach to anogenital LS.

Topical corticosteroids are the gold standard for treatment of genital LS in both adults and children and intralesional corticosteroids are also useful for treating areas of hyperkeratosis. Both retrospective and prospective studies have shown that ultrapotent topical corticosteroids (e.g. clobetasol propionate 0.05%) are highly effective in the treatment of *genital* LS[84–86]. In boys with genital LS, topical corticosteroids can avoid circumcision in one-third of patients[87].Topical calcineurin inhibitors, although less potent than the recommended class I corticosteroids, also have a role in topical therapy[84,85]. Ointments are preferred over creams because they are better tolerated, and frequent use of emollients (e.g. petrolatum) is also recommended. Topical JAK inhibitors (e.g. ruxolitinib 1.5% cream) are currently under investigation for anogenital LS.

Failure to respond to ultrapotent local corticosteroids should prompt evaluation for contributing factors, such as improper use of the corticosteroids, secondary infection (e.g. candidiasis), menopause-related vulvovaginal atrophy, and development of SCC. Second-line therapeutic options for *genital LS* have more limited efficacy data but include systemic agents (e.g. acitretin, abrocitinib)[88,89,89a].

Importantly, because symptoms often recur upon discontinuation of initial therapy and because of the long-term risk of malignancy (i.e. SCC), it is now recommended that patients follow a long-term maintenance regimen upon resolution of signs (e.g. hyperkeratosis, ecchymoses, fissures) and symptoms (e.g. pruritus) after ~6–12 weeks of induction therapy. Follow-up at regular intervals until a stable maintenance regimen is in place is advised, as is annual genital examination to exclude the development of malignancy.

Phototherapy

Phototherapy, primarily UVA1, has shown efficacy in some patients with genital LS and can be considered if topical/intralesional corticosteroids have failed. The long-term safety of UVA1 therapy in the genital region is unknown[90,91]. The successful use of photodynamic therapy (PDT) for vulvar LS has been reported in small case series and reports. Additional studies are needed to evaluate the role of PDT in treating genital LS.

Downloaded for Anonymous User (n/a) at Egyptian Knowledge Bank from ClinicalKey.com by Elsevier on March 10, 2024. For personal use only. No other uses without permission. Copyright ©2024. Elsevier Inc. All rights reserved.

Surgery

Circumcision is the treatment of choice for genital LS complicated by phimosis or paraphimosis. Excellent results have been reported[92]. Surgery in vulvar LS is indicated for the treatment of coexistent vulvar intraepithelial neoplasia, SCC, or fusion. LS will frequently recur around the scarring in females[93]. Lastly, fractional laser ablation has been used for treatment of hyperkeratotic LS plaques.

Extragenital Lichen Sclerosus

Fewer studies exist for the treatment of *extragenital* LS. Phototherapy and weekly methotrexate +/– systemic corticosteroids are potential treatment options for widespread disease, while potent topical corticosteroids and topical vitamin D analogues (e.g. calcipotriene [calcipotriol]) +/– under occlusion as well as topical calcineurin inhibitors are options for more limited disease[86,93]. When available, UVA1 phototherapy is preferred for widespread extragenital LS, followed by NB-UVB and then PUVA. The largest study to date of successful phototherapy for treating extragenital LS involved 10 patients who received 40 UVA1 sessions at a dose of 20 J/cm^2 four times/week[94]. Case reports exist for successful use of NB-UVB and PUVA[95–97].

Systemic immunosuppressive therapy is typically reserved for widespread cases that are refractory to phototherapy or in those patients who cannot undergo phototherapy. Weekly methotrexate alone (10–20 mg/week) or in combination with systemic corticosteroids (either pulsed [e.g. intravenous methylprednisolone 1000 mg/day for 3 consecutive days/month] or daily dosing [e.g. prednisone 1 mg/kg/day]) has shown efficacy in case reports and small case series[98–100]. In a case report, dupilumab led to improvement.

Additional figures available in our eBook (see inside front cover for access code).

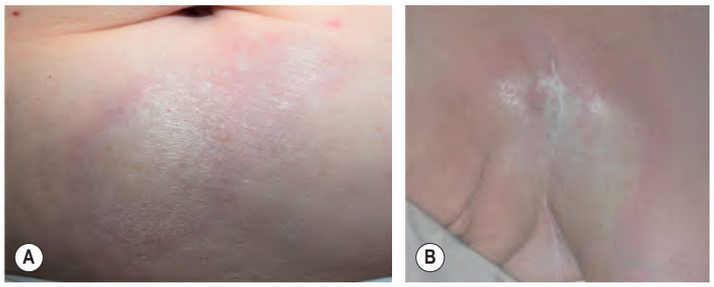

eFig. 44.1 Plaque-type/circumscribed morphea. Shiny, ivory-colored plaques of the abdomen (**A**) and chest (**B**) surrounded by a lilac ring. Wrinkling is obvious within the abdominal plaque. *Courtesy Kalman Watsky, MD.*

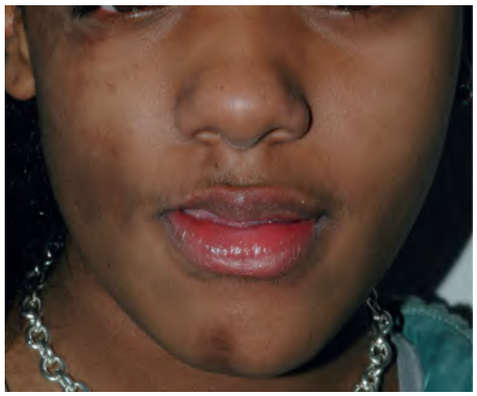

eFig. 44.3 Parry–Romberg syndrome. Hyperpigmentation and loss of subcutaneous fat, leading to facial asymmetry. *Courtesy Julie V. Schaffer, MD.*

eFig. 44.2 Nodular/keloidal morphea. Elevated, firm pink papulonodules arising within an area of hyperpigmented induration. *Courtesy Jean L. Bolognia, MD.*

eFig. 44.4 Morphea *en coup de sabre*. Linear depressions and sclerosis are more frequently paramedian (rather than midline) and can be thin. *Courtesy Julie V. Schaffer, MD.*

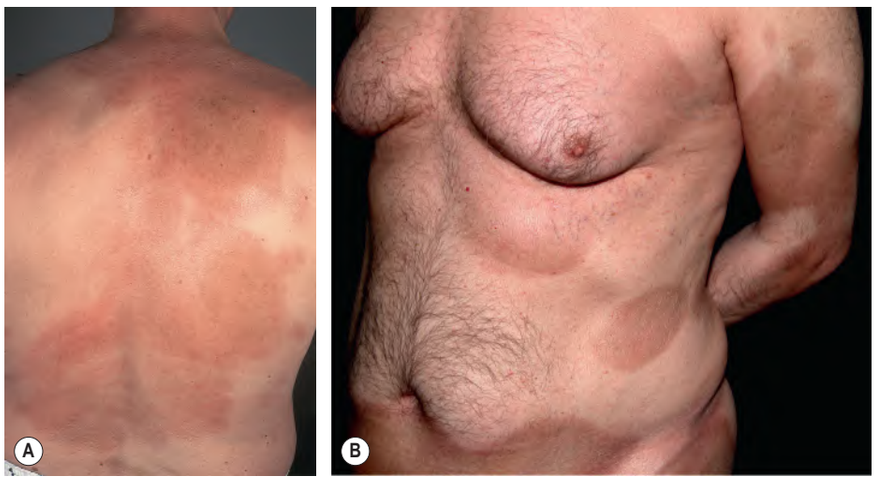

eFig. 44.5 Generalized morphea. Multiple, large hyperpigmented plaques, several of which have an inflammatory border, involving the posterior trunk (**A**) versus the anterior trunk and arm (**B**). *B, Courtesy Luis Requena, MD.*

Downloaded for Anonymous User (n/a) at Egyptian Knowledge Bank from ClinicalKey.com by Elsevier on March 10, 2024. For personal use only. No other uses without permission. Copyright ©2024. Elsevier Inc. All rights reserved.

eFig. 44.6 Radiation-induced morphea. Erythema and induration of the right neck. *Courtesy Kalman Watsky, MD*.

eFig. 44.9 Extragenital lichen sclerosus. White papules and small plaques on the neck.

eFig. 44.7 Linear morphea of the leg in an adolescent. Extensive induration of the left leg with hypoplasia and an obvious flexion contracture of the knee; there is also involvement of the right foot.

eFig. 44.10 Hemorrhagic bullae within extragenital lichen sclerosus. The explanation is fragility of the dermal–epidermal junction.

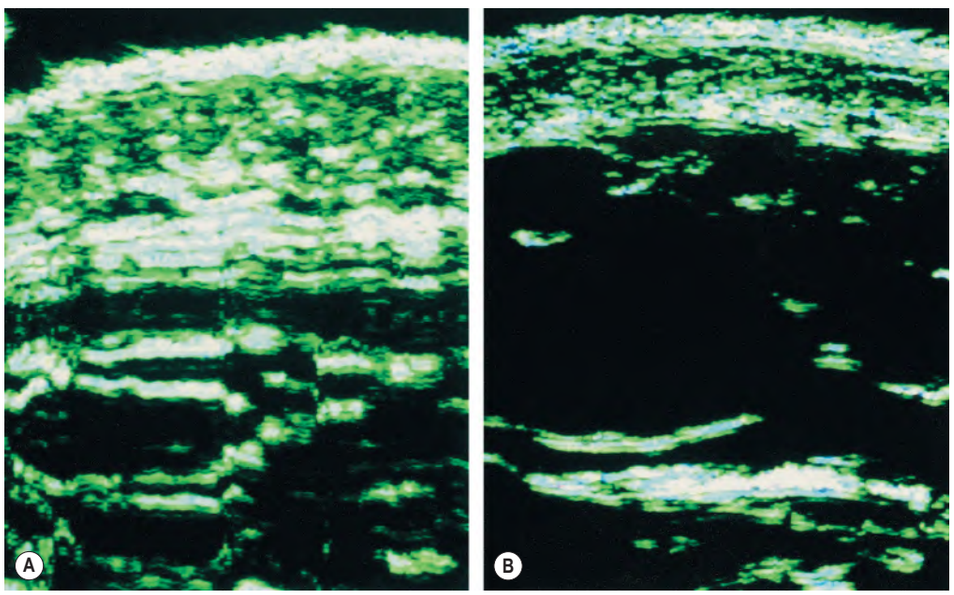

eFig. 44.8 High-frequency ultrasound (20 MHz) of a morphea plaque. Before (**A**) and after (**B**) PUVA bath photochemotherapy, showing reduction of dermis thickness and hyperechoic bands of connective tissue.

Downloaded for Anonymous User (n/a) at Egyptian Knowledge Bank from ClinicalKey.com by Elsevier on March 10, 2024. For personal use only. No other uses without permission. Copyright ©2024. Elsevier Inc. All rights reserved.

eFig. 44.11 Lichen sclerosus of the glans penis with extension onto the shaft. Note the hypopigmentation and purpura as well as scarring and ongoing inflammation. *Courtesy Kalman Watsky, MD.*

eFig. 44.12 Anogenital lichen sclerosus. The distribution pattern has a figure-of-eight configuration. The presence of purpura is also a clue to the diagnosis. *Courtesy Jeffrey P. Callen, MD.*

eFig. 44.13 Lichen sclerosus-like changes in a patient with chronic graft-versus-host disease. *Courtesy Dennis Cooper, MD.*

eFig. 44.14 Radiation-induced morphea and lichen sclerosus. The majority of indurated plaques are hyperpigmented but note the hypopigmented plaque at 3 o'clock. *Courtesy Jeffrey P. Callen, MD.*

Downloaded for Anonymous User (n/a) at Egyptian Knowledge Bank from ClinicalKey.com by Elsevier on March 10, 2024. For personal use only. No other uses without permission. Copyright ©2024. Elsevier Inc. All rights reserved.

eFig. 44.15 Ultrapotent topical corticosteroids in the treatment of lichen sclerosus. Before (**A**) and after (**B**) application of clobetasol propionate 0.05% cream daily for 5 months in this 12-year-old girl.

Downloaded for Anonymous User (n/a) at Egyptian Knowledge Bank from ClinicalKey.com by Elsevier on March 10, 2024. For personal use only. No other uses without permission. Copyright ©2024. Elsevier Inc. All rights reserved.